

Comparison of guided and non-guided implant placement accuracy

In vitro study with 3D printing (Part 2)

Marta Czajkowska, Dr Łukasz Zadrożny, Zbigniew Bartosik & Dr Leopold Wagner, Poland

Introduction

Proper 3D implant positioning is a crucial factor for predictable implant and prosthodontic treatment. Guided osteotomy preparation and placing implants through a guide may contribute to more precise implant placement in accordance with the prosthodontic plan. In the first part of the article (published in **CAD/CAM** 1/2019), we described the use of 3D imaging in implant treatment planning. This study aims at the comparison of two methods in terms of repeatability and compliance with the treatment plan.

Aim of the second part of the study

The aim of the second part of the study is to present the methods of comparison of effects for both types of procedures and the initial results.

Material

The guide was sterilised and clinically used during the procedure repeated under the *in vitro* conditions on half of the selective laser sintered mandibular models

(material: polyamide 12; 3D printer: TPM Elite P3200 SLS system; print: Solveere). The procedure was performed freehand for the other half of the models. The mandibular models, created on the basis of 3D imaging, reflected the clinical spatial conditions.

The comparative material consisted of scans of the bone bearing the implants (TSIII with standard mounts, Osstem Implant) and scans of the model of the treatment plan with inserts. The bone scans were performed with the use of the laboratory scanner ceramill map 400+ (Amann Girrbach) and saved in STL open files. The files are maps of triangles describing the surface of the 3D model. Each triangle vertex has coordinates. The denser the net of triangles, the smaller the area of the real model covered by each triangle. According to the manufacturer, the scanner accuracy is 10 µm. The compared material consisted of two STL files of the scans of models in which the implantation procedure was performed with the use of the guide, an STL file of the scan of the model after implantation performed freehand and an STL file of the virtual plan of the procedure. The file of the virtual plan was a reference point for the calculation of deviations in the groups with and without the use of the guide.

The implantation procedure was planned in DDS-Pro software (www.dds-pro.com.pl) on the basis of the CBCT scan and the optical scan of the cast model and of the model with the wax-up of the future prosthesis. In this manner, the image of the bone and mucosa surface and the localisation and the shape of the future prosthesis were obtained.

In the next step, based on the implant location plan, a digital model with inserts located in the sites of the future implants was created. Each virtual insert was located exactly in the site of the virtual implant platform and was in the shape of a cylinder with a diameter of 3.0mm and height of 8.5mm.

Methodology

In order to compare the samples from both groups—bone scans with implants placed freehand and with the use of guides—HP 3D Scan Version 5 software (HP) was used. Data was recorded using two methods: based on the maps of deviations and on the measuring points. For each scan, 30 maps were created, based on tolerance levels of 0.01 to 3.01 mm in 0.1 mm increments (Fig. 1).

Next, for each implant, a tolerance level was chosen for which there were no areas on the map showing variations exceeding this level. In this way, the levels not exceeded by the deviation of the implant and insert locations were established for each implant individually. The next stage of the study was finding the areas with deviations exceeding this level on the tolerance level lower by 0.1 mm (one tolerance level) than the level established for each implant. These areas were marked in pink. By choosing a number of points located close to each other and choosing a point with the highest value in these areas, the points with the highest value of deviations were marked (Fig. 2).

In the second method, the measuring points were established on the reference model. The following points were marked on the upper surface of each insert (Fig. 3): central, mesial, distal, labial and lingual. Next, for each implant, the deviation of its location relative to these points was checked. Test models were changed successively, maintaining formerly set measuring points to avoid marking them again. The location of measurement points did not change relative to the insert, but depending on the test model, the deviation value assigned to these points did.




Fig. 1: Example of deviation maps set for FH01. The pink colour indicates areas where the deviations exceeded the tolerance level established for the particular map; the remaining colours indicate areas within the accepted range.

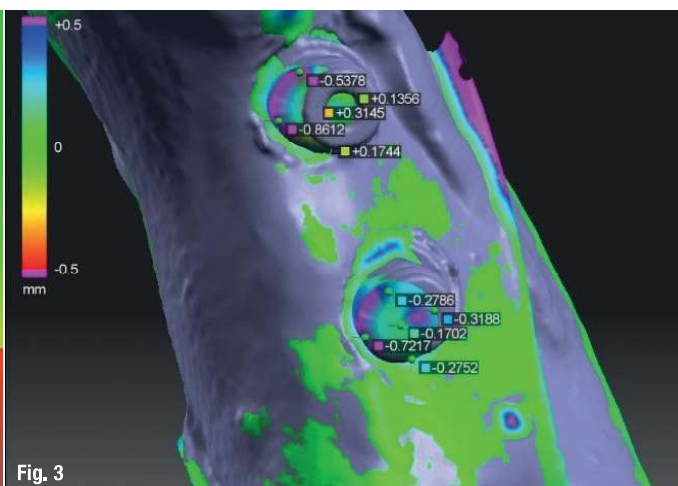
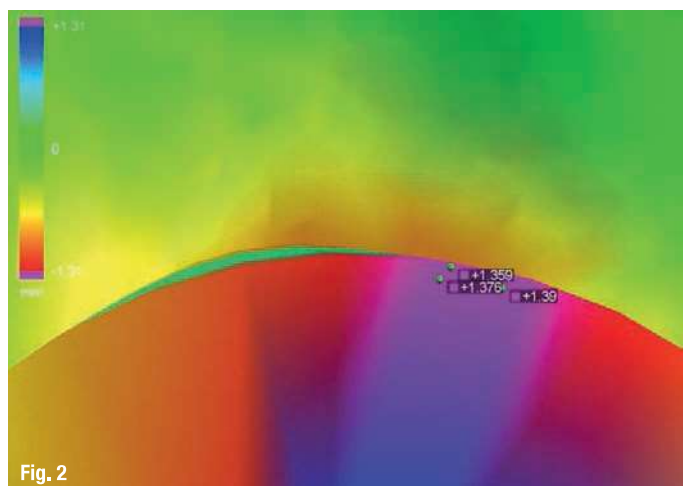


Fig. 2: An example of the area where the established tolerance level for implant FH01I was exceeded, with some point deviations marked. **Fig. 3:** The placement of measuring points on implants WG01rm and WG01rd. The grey test model with implants was superimposed upon the reference model and deviation levels marked.

This allowed us to maintain repeatability of measurements while testing other models.

Preliminary results of the comparison are shown in the figures. The smallest deviations were visible on implant WG02I, and the largest deviations were on implant FH01rm (Fig. 4). In order to compare the groups, a larger

number of samples should be studied, but after the comparison of three initial models, we could see a great difference between implants placed with and without the help of guides. There was also a noticeable, differentiation in the degree of deviations in both groups of implants. In the case of implants placed with the help of guides and freehand, there were cases of small and large deviations.

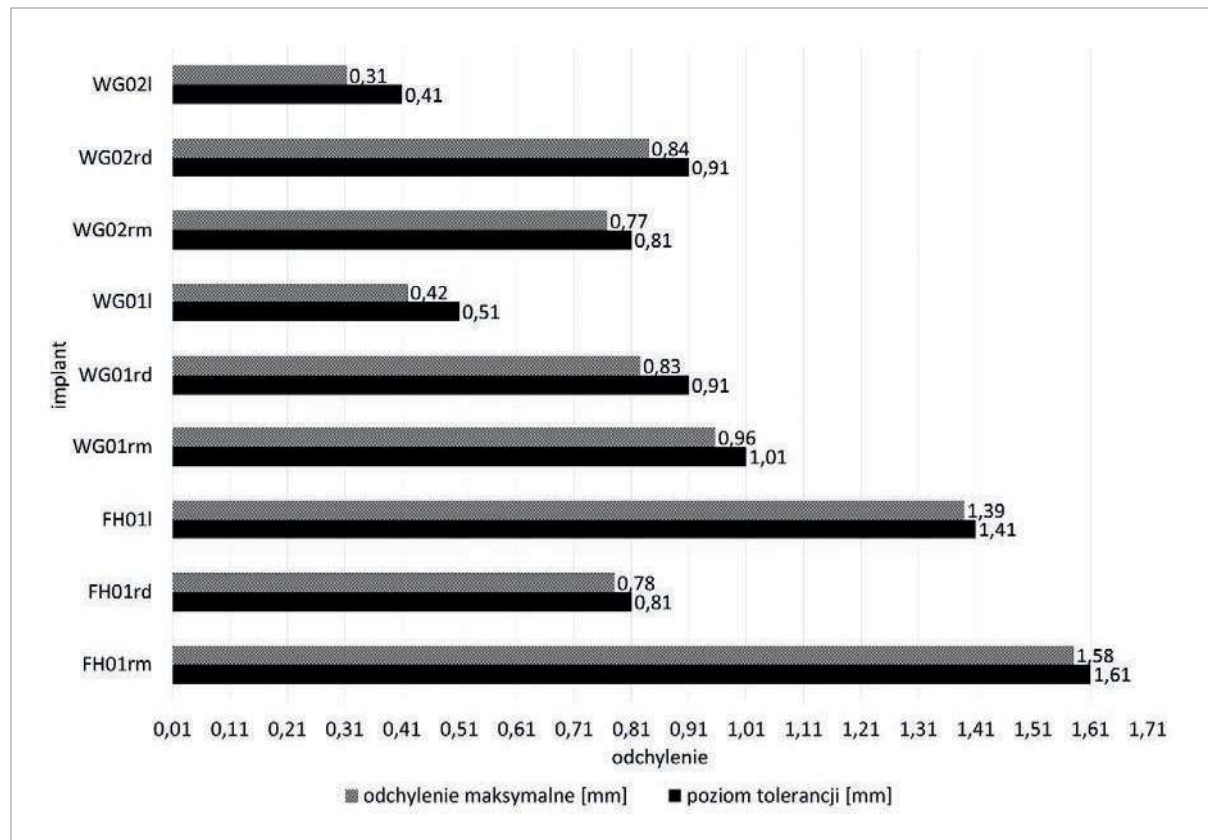


Fig. 4: Deviation levels for particular implants set with maximum point deviations. Implant naming: WG/FH, sample number, I/r, m/d (FH = freehand; WG = with guide; I = left; r = right; m = mesial; d = distal).

It should be noted that the differences between the levels where there were no longer any deviations and the maximum deviations were more similar for the procedures performed without the use of guides. This indicates that the treatment plan is followed more precisely when the guides are used.

Like in the first method, in order to compare both types of treatment, more samples should be compared. On the basis of the first three results, we observed that the greatest deviations appeared in the group of implants placed freehand (Fig. 5). In this group, larger differences between deviations at individual measuring points were noticeable. This demonstrates that the axes of the implant and the insert were inclined at a greater angle to each other and the upper surface of the implant was not parallel to the upper surface of the insert. This is especially evident for implants FH01rd and WG02l, which, despite having a similar mean deviation value, have a different degree of differentiation of deviations in the points (Figs. 6 & 7).

Discussion

Many factors affecting the success of implant surgery and its compliance with the treatment plan are reported in the literature. The most important of these are the type

of procedure, operator's experience and clinical conditions.

As digital technologies gain in significance, digital spatial imaging is increasingly used, as it allows consideration of not only the bone conditions but also the function and aesthetics of the future prosthetic restoration during the treatment planning. The use of CT or CBCT imaging enables reduction of the risk of damage of such structures as nerves, roots of adjacent teeth and the sinus wall. The implant procedure performed with the use of guides is assessed in systematic reviews as a technique which is less invasive and reduces the risk of postoperative complications.

Despite the limitations of this study, arising from the choice of an *in vitro* method aiming to achieve the highest repeatability of conditions in both groups, the preliminary results of the study are supported by the data obtained in the study conducted under clinical conditions.

Vermeulen shows that procedures performed with the use of implant guides give results more consistent with the treatment plan, even when compared with freehand procedures performed by top-class experienced surgeons. In the mentioned study, particularly important differences were seen in the deviation of implant placement

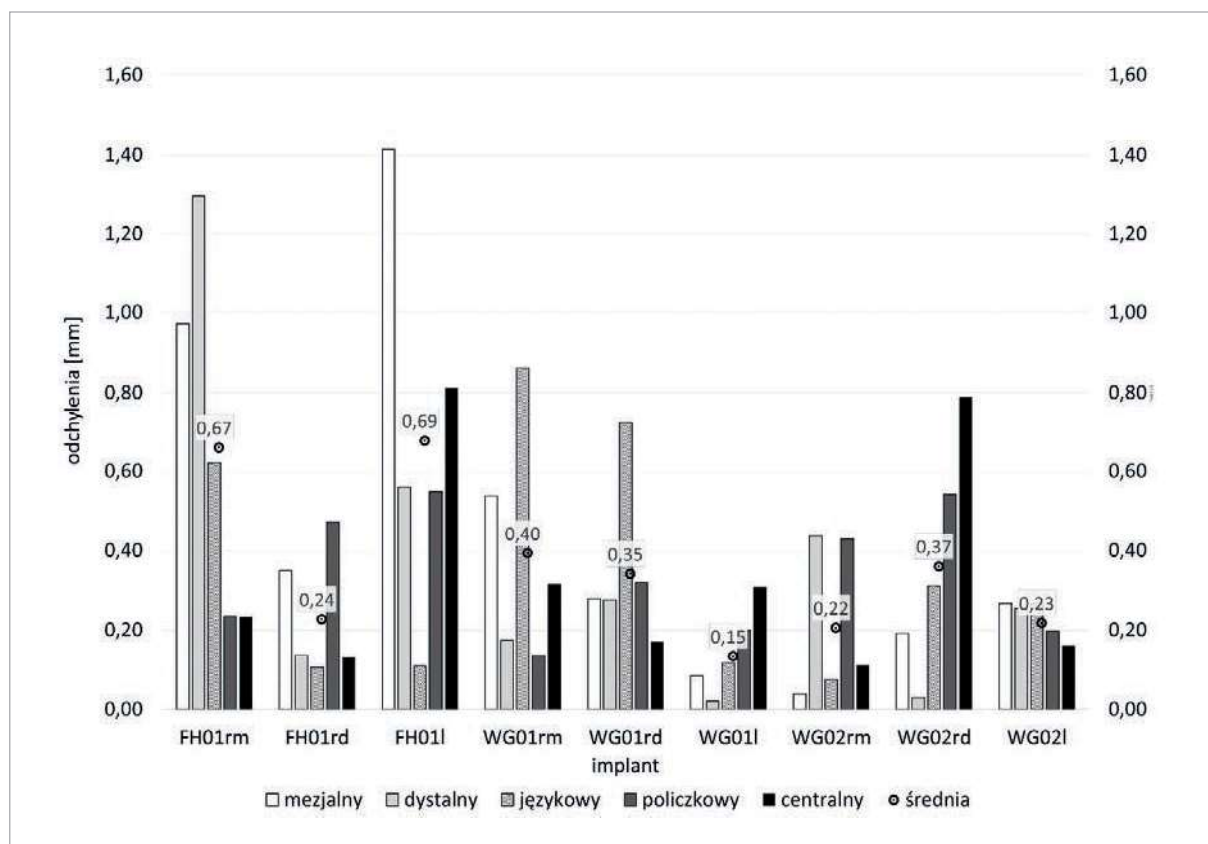


Fig.5: Absolute deviation values for implants in the areas of fixed measuring points on the inserts. Implant naming: WG/FH, sample number, l/r, m/d (FH = freehand; WG = with guide; l = left; r = right; m = mesial; d = distal).


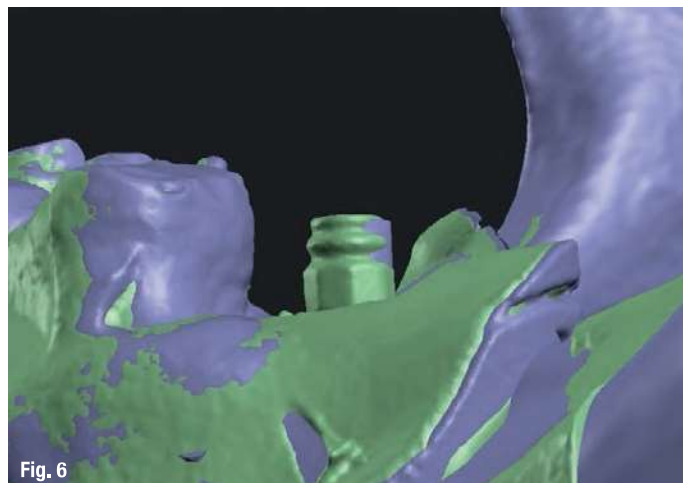


Fig. 6: Implant WG02l, buccal view. The figure shows two superimposed models. The green model is one with implants and the purple model one with inserts. The figure shows that the implant is displaced in relation to the insert, but their axes are approximately parallel to each other. **Fig. 7:** Implants FH01rm and FH01rd, lingual view. The figure shows two superimposed models. The green model is one with implants and the purple model one with inserts. It can be easily observed that, despite the small spatial displacement of the implant relative to the insert, their axes are convergent.

depth for the freehand procedures group compared with the guided procedures group. What is more, deviations of implant insertion angle were significantly greater in the freehand procedures group. This may have a potentially high impact on the need to change the prosthetic design accepted at the stage of preparation for treatment.

It should be noted that guided implantation procedures are also associated with many difficulties. Owing to the limited space between the drill and the sleeve, the full range of the implant insertion angle is impossible. According to Seong-Yong Moon et al., it is critically important to consider the design of the future prosthetic restoration at the stage of planning the procedure.

What limits the usage of a guide is the jaw grading for a particular patient. The study analysed the procedures performed in five patients, entailing placement of 19 implants: with the use of a guide supported on the patient's teeth for 11 implants, and on the mucosa for eight implants. Although it was finally concluded that the guided procedure is better than the freehand procedure, attention was paid to such significant limitations of the first method as limited jaw grading, the shape of a guide, difficulties in attaching the guide to the foundation, and the length of surgical drills.

In terms of the procedure, the most similar to the present study is that of Toyoshima et al., who analysed procedures performed by inexperienced operators with the use of guides under *in vitro* conditions. In the study description, the necessity of choosing *in vitro* conditions owing to the lack of experience of the operators was underlined. Despite the use of guides, the deviations in the implant insertion angle from the treatment plan were significant.

Conclusion

The initial conclusions of the study are consistent with the conclusions of scientific research analysis and confirm greater compliance with the treatment plan for implants placed in guided procedures. The comparison methods used and the research material selection in the form of STL files allowed us to analyse the procedure effect adjustment relative to the treatment plan.

Editorial note: The study is being carried out as a part of a project in the field of scientific developmental research aimed at the development of young scientists and students enrolled in PhD studies, financed as part of the scientific activity of the Medical University of Warsaw in Poland. A list of references is available from the publisher.

contact

Dr Łukasz Zadrozny, DDS, PhD and **Dr Leopold Wagner, DDS, PhD** are employed at the Department of Dental Propedeutics and Prophylaxis of the Dentistry Division of the Medical University of Warsaw. They can be contacted at lukasz.zadrozny@wum.edu.pl and leopold.wagner@wum.edu.pl.

Marta Czajkowska is a member of the Student Scientific Association in the Department of Dental Propedeutics and Prophylaxis of the Dentistry Division of the Medical University of Warsaw. She can be contacted at mrtczaikowska@gmail.com.

Zbigniew Bartosik is a dental technician and focused on digital solutions at Natrodent, Łódź. He can be contacted at zbigniew.bartosik@natrodent.pl.